

# Multiple pulmonary metastases from asymptomatic benign intracranial meningioma: a case report

## Daugybines plaučių metastazės iš besimptomės gerybinės intrakranijinės meningiomos: klinikinis atvejis

Jurgita Ušinskienė<sup>1</sup>, Evelina Šestelinska<sup>2</sup>, Laura Neverauskienė<sup>3</sup>,  
Simona Rūta Letautienė<sup>1,2</sup>, Saulius Ročka<sup>2,4</sup>

<sup>1</sup> Department of Radiology, National Cancer Institute, Santariškių Str.1, LT-08660 Vilnius, Lithuania

<sup>2</sup> Vilnius University Faculty of Medicine, M. K. Čiurlionio Str. 21, LT-03101 Vilnius, Lithuania

<sup>3</sup> LLC Pathology Diagnostics, Šiltnamių Str. 29, LT-08406 Vilnius, Lithuania

<sup>4</sup> Department of Neurosurgery, Republican Vilnius University Hospital, Siltnamių Str. 29, LT-04130 Vilnius, Lithuania  
E-mail: jurgita.usinskiene@nvi.lt

<sup>1</sup> Nacionalinio vėžio instituto Radiologijos skyrius, Santariškių g. 1, LT-08660 Vilnius, Lietuva

<sup>2</sup> Vilniaus universiteto Medicinos fakultetas, M. K. Čiurlionio g. 21, LT-03101 Vilnius, Lietuva

<sup>3</sup> LLC Patologijos diagnostika, Šiltnamių g. 29, LT-08406 Vilnius, Lietuva

<sup>4</sup> Respublikinės Vilniaus universitetinės ligoninės Neurochirurgijos skyrius, Šiltnamių g. 29, LT-04130 Vilnius, Lietuva  
El. paštas: jurgita.usinskiene@nvi.lt

---

### Introduction

This case presents unexpected association between disease and symptoms. We believe that it should compel clinicians to rethink the known behaviors of the benign tumors, in particular meningioma which can gain independent metastatic potential. This report aims to increase the awareness of clinicians toward patients with this unusual and clinically isolated pattern, because metastases can remain misdiagnosed for a long period of time. This case contributes to medical knowledge, diagnostic and prognostic approaches. This is also the first case of metastatic meningioma reported in Lithuania.

### Case report

We report a 66-year-old woman who presented with persistent productive cough, dyspnea, fever and weakness during physical activity. Chest radiographs revealed multiple small round shaped pulmonary nodules. Thoracoscopic resection and histopathology showed a benign meningioma. Magnetic resonance imaging (MRI) scan of the brain demonstrated a small dural-based mass in the left pontocerebellar angle connected with deep dilated cerebral venous network and superior petrosal sinus. Morphological findings of this tumor were consistent with a World Health Organization (WHO) grade I fibrous meningioma.

## Conclusion

Meningiomas are usually non-invasive tumors and do not metastasize and hence, are perceived as benign tumors. Patients with this uncommon and clinically isolated pattern of metastases can remain misdiagnosed for a long period of time, due to unexpected behavior of this particular tumor. This case report denies most of the criteria of possible risk factors for the development of metastases from a meningioma what allows to consider it as tumor with unpredictable behavior.

**Key words:** meningioma, benign, asymptomatic, metastases

---

## Įvadas

Šis kliniškinis atvejis atspindi nenumatytą ligos pasireiškimą. Tikime, kad jis privers apgalvoti jau žinomą gerybinių navikų, tarp jų ir meningiomas, elgseną, kuri gali įgyti nepriklausomą metastazinį potencialą. Kadangi gerybinių navikų metastazės yra diagnozuojamos pavėluotai, šiuo pavyzdžiu siekiame plėsti kliniциstų sąmoningumą ir budrumą nagrinėjant ligas, kurioms būdingos neįprastos kliniškinės apraiškos. Tai pirmasis Lietuvoje aprašytas intrakranijinės meningiomas metastazavimo į plaučius atvejis.

## Kliniškinis atvejis

Aprašome 66 metų moters atvejį. Ji skundėsi nuolatiniu produktyviu kosuliu, dusuliu, karščiavimu ir silpnumu, atsirandančiu fizinio krūvio metu. Krūtinės ląstos rentgenogramos parodė daugybinius, mažus, apvalios formos mazgus plaučiuose. Po atliktos torakoskopinės plaučių rezekcijos histopatologinio tyrimo būdu konstatuota meningioma. Atliktas galvos smegenų magnetinio rezonanso tyrimas, kurio išvada – kairiajame tilto ir smegenėlių kampe su dangalais susijęs, kontrastinę medžiagą gerai kaupiantis, smulkus navikas, išsiplėtusios giliosios smegenų venos. Histologiškai smegenų darinys, remiantis Pasaulio sveikatos organizacijos klasifikacija, yra I laipsnio fibrozinė meningioma.

## Apibendrinimas

Meningioma yra traktuojama kaip neinvazinis ir nemetastazuojantis, gerybinis, intrakranijinis navikas. Metastaziniai židiniai yra neįprasti šios ligos eigai, dėl to gali būti diagnozuoti pavėluotai. Kliniškinis atvejis paneigia literatūroje nurodytus rizikos veiksnius, kuriais remiantis būtų galima numatyti galimą meningiomas metastazavimą, kas leidžia priskirti meningiomą ne-prognozuojamos eigos navikams.

**Reikšminiai žodžiai:** meningioma, gerybinis navikas, besimptomė eiga, metastazės

---

## Introduction

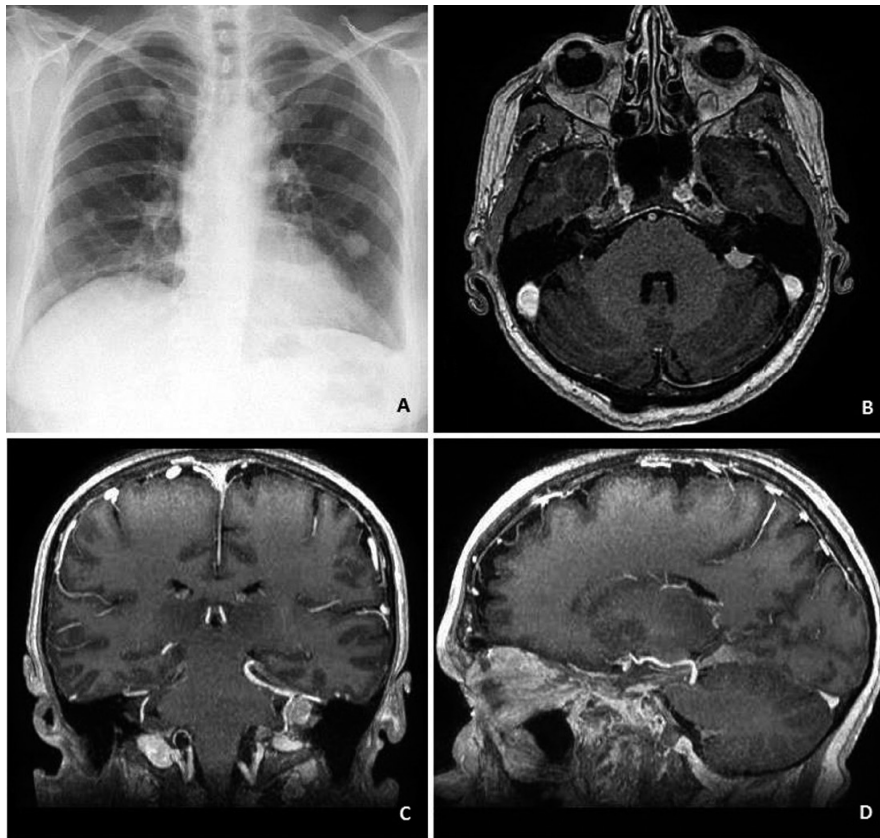
Meningioma is the most common primary extra-axial tumor of the central nervous system in adults [1, 2], and arises from the meningoepithelial cells of the leptomeninges. Extracranial metastases of meningiomas are rare and occur in less than 1 per 1000 cases [3, 4, 5, 6]. The most common site of metastasis is the lung, which counts for 61% of all meningioma metastases [7, 8], followed by the liver, lymph nodes, and bones [9]. There are only isolated case reports, regarding pulmonary meningioma metastases, most of which, as the presented case, were incidentally detected by chest radiography or Computed tomography (CT) scans [10, 11].

We present a case of 66 year old woman who showed acute symptoms of pneumonia. Chest x-ray revealed pulmonary metastases, the origin of which turned to be asymptomatic benign meningioma of pontocerebellar region.

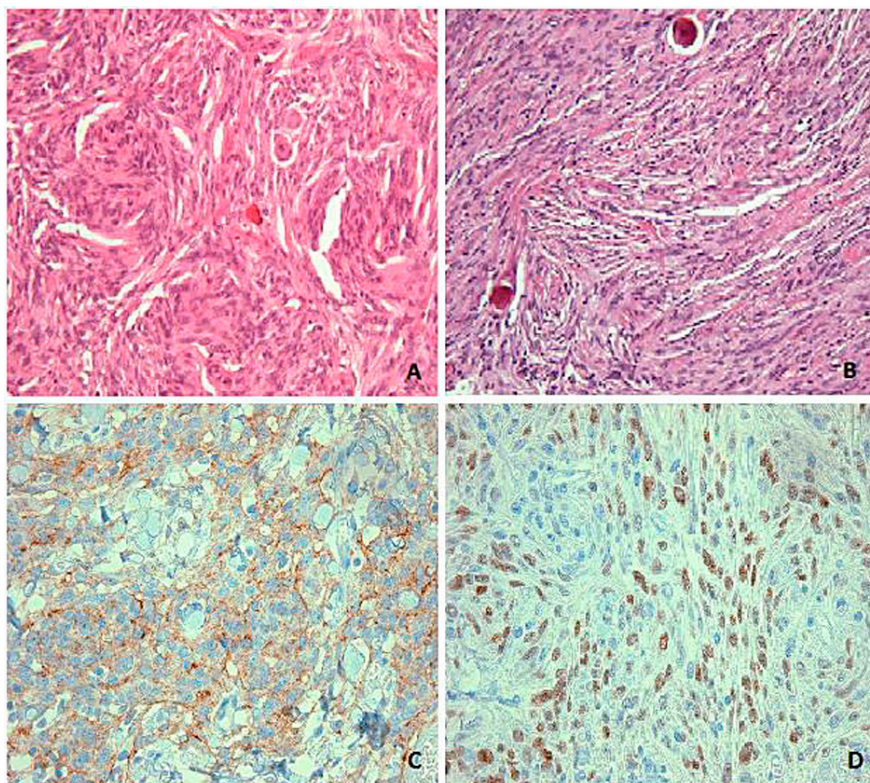
## Case report

A 66 year old woman presented with persistent productive cough, dyspnea, fever and weakness during physical activity. Respiratory system examination displayed stable hemodynamic, bronchovesicular breathing on both sides, persistent cough with observable watery phlegm was noted. Laboratory testing showed increased white cells count. Firstly pneumonia was expected, but chest radiographs unveiled multiple small round shaped pulmonary nodules (Fig. 1A). This discovery led to the necessary histopathology testing to discard other possible diseases forming nodules such as tuberculosis or malignant tumors. The patient was referred to a local university hospital for further analysis.

Diagnostic thoracoscopic resection of mediastinal masses was performed and histopathology showed meningioma (WHO grade I) (Fig. 2A). Lung mass was positive for Epithelial membrane antigen (EMA) (cyto-



**Fig. 1.** Radiological findings  
 A. Chest radiograph shows multiple round shaped lesions in both lobes.  
 B. C. D. Contrast enhanced T1 brain MRI shows the dural-based homogeneously enhancing mass (9 × 6 mm) at left ponto-cerebellar angle with dilated deep cerebral veins and superior petrosal sinus



**Fig. 2** Morphological findings in consistent with a WHO grade I fibrous meningioma  
 A. Histopathological examination of the pulmonary lesion shows oblong-shaped cells with oval nuclei and intranuclear pseudoinclusions.  
 B. Histopathological examination of brain mass shows oblong-shaped cells with slightly polymorphic nuclei, abundant eosinophilic cytoplasm and average cellularity, without mitotic activity. The tumor consists of meningotheial cells arranged in fascicles with psammoma bodies.  
 C. Lung mass positive for EMA (cytoplasmic staining)  
 D. Lung mass positive for PR (nuclear staining)



Risk factors for the development of metastases from a meningioma include histological criteria such as:

1. cellularity,
2. cellular heterogeneity,
3. high mitotic rate,
4. nuclear pleomorphism,
5. tumor necrosis,
6. invasion of adjacent blood vessels.

Case report findings
<ul style="list-style-type: none"> <li>• oblong-shaped cells</li> <li>• slightly atypical nuclei</li> <li>• average cellularity, without mitotic activity</li> <li>• cells arranged in fascicles</li> <li>• very low Ki-67 proliferation index</li> </ul>

Kanthan R, Senger JL. Distant metastases from meningiomas – A myth or reality? 2013; *Ann Clin Pathol* 1(1): 1001.

The literature suggests that

- craniotomy,
- venous sinus invasion,
- local recurrence,
- papillary morphology,
- histological malignancy

Case report findings
<ul style="list-style-type: none"> <li>• no previous craniotomy</li> <li>• no venous sinus invasion</li> <li>• no local recurrence</li> <li>• no papillary morphology</li> <li>• grade I fibrous meningioma</li> </ul>

may be risk factors for systemic spread.

T. Eran, I. Hanta, S. Hacıyakupoğlu, S. Zorludemir, H. Zeren, and A. I. Göçer. Huge bilateral pulmonary and pleural metastasis from intracranial meningioma: A case report and review of the literature. *Journal of Neuro-Oncology*, vol. 74, no. 2, pp. 179-181, 2005.

Adlakha A, Rao K., Adlakha H, Perry A, Crotty T, Scheithauer BS et al. Meningioma metastatic to the lung. *Mayo Clinic Proceedings*, vol. 74, no. 11, pp. 1129-1133, 1999.

plasmic staining (Fig. 2C)) and Progesterone receptor (PR) (nuclear staining (Fig. 2D)). Immunohistochemical stainings for CD34, CD117, CD99, Actin, Desmin, S100, panCK, TLE-1 were negative.

Patient was conscious and oriented, neurological examination showed no signs of neurologic deficit: symmetrical pupils with positive photoreaction and free eye movement; symmetrical face with sensations not affected, and no visible meningeal symptoms. Limb tone, movements and tendon reflexes without any pathological symptoms. MRI scan of the brain revealed the dural-based contrast enhancing mass (9x6 mm) at the left ponto-cerebellar angle connected with dilated venous network, deep left cerebral veins and superior petrosal sinus (Fig. 1B). No perifocal reaction or mass effect was found.

Total surgical resection of the tumor mass via left retrosigmoidal approach was performed. Histopathological examination of the brain mass (Fig. 2B) showed oblong-shaped cells with slightly atypical nuclei, abundant eosinophilic cytoplasm and average cellularity, without mitotic activity. The tumor consists of meningothelial cells arranged in fascicles with psammoma bodies. Ki-67 proliferation index was very low. Morphological findings were consistent with a WHO grade I fibrous meningioma.

Histopathological examination parameters of the intracranial tumor matched those of the lung mass. Histological findings together with the clinical history were suggestive of a metastatic meningioma WHO grade I.

After the surgery, patient showed no postoperative neurological deficiencies. Within first twenty four hours, patient was treated with analgetics, single dose of antibiotics (Cephazoline) and anticoagulant for deep vein thrombosis prophylactics. Physical rehabilitation was started for early vertigo control. After surgery CT showed small air spaces and postoperative alteration with no signs of bleeding. Surgical incision healed without any contamination, sutures were removed and patient was discharged from hospital. It was recommended to consult a neurologist and neurosurgeon after 6 months for examination and control MRI checkup.

After half a year, MRI examination showed no signs of brain tumor recurrence. Currently the patient is being treated for lung masses in her local hospital. In view of the slow-growing nature of these metastases and their good prognosis after resection, surgery is the treatment of choice [12].

## Discussion

Meningiomas (WHO grade I) are usually non-invasive tumors and do not metastasize and hence, are perceived as benign tumors [12]. However, a larger number of meningiomas (approximately 20%) exhibit aggressive behavior, with approximately 1% of all patients with meningiomas developing distant metastases [13, 14, 15, 16].

Risk factors for the development of metastases from a meningioma include histological criteria such as cellularity, cellular heterogeneity, high mitotic rate, nuclear pleomorphism, tumor necrosis, and invasion of adjacent blood vessels [17]. In our patient, review of the histo-

logical appearances of the primary and metastatic tumor revealed no signs of malignancy. Case showed that, a high cell proliferation rate and other histological criteria are not essential for the occurrence of extracranial metastases and histologically benign meningioma can possibly metastasize [5].

The literature suggests that previous craniotomy, venous sinus invasion, local recurrence, papillary morphology, and histological malignancy may be risk factors for systemic spread [18, 19]. As seen in the case of our patient, metastatic meningioma may present without previous local tumor recurrence or histological malignancy.

## REFERENCES

1. Kaminski JM, Movsas B, King E, Yang C, Kronz JD, Alli PM et al. Metastatic meningioma to the lung with multiple pleural metastases. *Am J Clin Oncol* 2001; 24: 579–582.
2. Ostrom QT, Gittleman H, Farah P, Ondracek A, Chen Y, Wolinsky Y et al. CBTRUS Statistical Report: Primary Brain and Central Nervous System Tumors Diagnosed in the United States in 2006–2010. *Neuro Oncology* 2013; 12: ii15–ii56.
3. Teague SD, Conces Jr DJ. Metastatic meningioma to the lungs. *J Thorac Imaging* 2005; 20: 58–60.
4. Vik A, Kvikstad A, Unsgard G, Jorgensen JV, Torp SH. A 54-year-old man with a large subcutaneous skull erosion and focal epileptic seizures. *Tidsskr Nor Laegeforen* 2006; 126: 2386–2387.
5. Erman T, Hanta I, Hacıyakupoglu S, Zorludemir S, Zeren H, Göçer A. Huge bilateral pulmonary and pleural metastasis from intracranial meningioma: a case report and review of the literature. *J Neurooncol* 2005; 74: 179–181.
6. Estanislau ES, Carvalho GTC, Reis BL, Barbosa WF, Brandao RACS, Sousa AA et al. Malignant meningioma with extracranial metastases. *J Neuropsiquiatr* 2009; 67(3A): 730–732.
7. Nathoo N, Ugokwe K, Chang AS, et al. The role of 111indium-octreotide brain scintigraphy in the diagnosis of cranial, dural-based meningiomas. *J Neurooncol* 2007; 81: 167–174.
8. Karasick JL, Mullan SF. A survey of metastatic meningiomas. *J Neurosurg* 1974; 40: 206–212.
9. Basunaid S, Franssen FME, Accord R et al. Case Report: Pulmonary metastases of malignant meningioma. *Research* 2014; 2: 222.
10. Nakano M, Tanaka T, Nakamura A, Watanabe M, Kato N, Arai T et al. Multiple Pulmonary Metastases following Total Removal of a Bilateral Parasagittal Meningioma with Complete Occlusion of the Superior Sagittal Sinus: Report of a Case. *Case Reports in Neurological Medicine* 2012; 12: 1–7.
11. Alexandru D, Glantz JM, Kim L, Chamberlain MC, Bota DA. Pulmonary metastases in patients with recurrent, treatment – resistant meningioma. *J Cancer* 2011; 10: 2–6.
12. Kleihues P, Cavenee WK. *Pathology and Genetics of Tumors of the Nervous System*, World Health Organization, IARC, Lyon, France, 2007.
13. Rockhill J, Mrugala M, Chamberlain MC. Intracranial meningiomas: an overview of diagnosis and treatment. *Neurosurg Focus* 2007; 23: E1.
14. Burger PC, Scheithauer BW. *Meningioma 2007: Tumors of the Central Nervous System*. Washington DC, Armed Forces Institute of Pathology 2007, p. 331–362.
15. Louis DN, Scheithauer BW, Budka H, von Deimling A, Kepes JJ. Meningiomas. In: Kleihues P, Cavenee WK, eds. *2000 WHO Classification of Tumors. Tumors of the Nervous System*. Lyon, France, IARC 2000, p. 175–196.
16. Perry A, Stafford SL, Scheithauer BW, Suman VJ, Lohse CM. Meningioma grading: an analysis of histologic parameters. *Am J Surg Pathol* 1997; 21: 1455–1465.
17. Kanthan R, Senger JL. Distant metastases from meningiomas – A myth or reality? 2013; *Ann Clin Pathol* 1(1): 1001.
18. Erman T, Hanta I, Hacıyakupoğlu S, Zorludemir S, Zeren H, Göçer AI. Huge bilateral pulmonary and pleural metastasis from intracranial meningioma: a case report and review of the literature. *J Neuro Oncol* 2005; 74(2): 179–181.
19. Adlakha A, Rao K, Adlakha H, Perry A, Crotty T, Scheithauer BS et al. Meningioma metastatic to the lung. *Mayo Clinic Proceedings* 1999; 74(11): 1129–1133.

## Conclusions

The present case report emphasize the importance of performing careful examination for patients, to detect and treat any distant metastases as early as possible, even though they occur rarely. The benign meningioma not only can become malignant, but also can acquire independent metastatic potential and metastasize outside central nervous system. In reference to our case, we can state that there are no definitive criteria to predict local recurrence or metastases what allows to consider meningioma as tumor with unpredictable behavior.